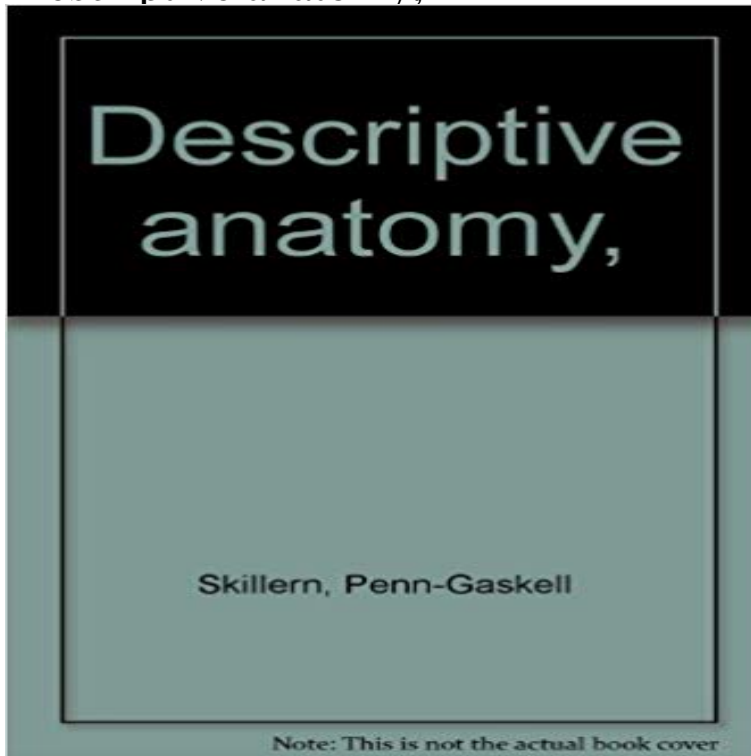


Descriptive anatomy,



This historic book may have numerous typos and missing text. Purchasers can usually download a free scanned copy of the original book (without typos) from the publisher. Not indexed. Not illustrated. 1910 edition. Excerpt: ... the coronoid process of the ulna during flexion, and the larger olecranon fossa behind, which receives the apex of the olecranon process of the ulna during extension. The external condyle, less prominent and forwardly inclined, shows in its articular portion the globular capitellum (little head), which articulates with the concavity on the summit of the radius, and is bounded internally by a shallow groove for the inner margin of the head of the radius, and above by the slight radial fossa for the anterior margin of the head of the radius in complete flexion of the forearm, while its non-articular portion shows the flat, irregular, forwardly-curved and smaller external epicondyle, which is continuous with the external supracondylar ridge, and gives origin above to the common tendon of the extensor carpi radialis brevis, extensor digitorum communis, extensor minimi digiti, extensor carpi ulnaris, and supinator, below and before to the external lateral ligament, and below and behind to the anconeus. The margins of the coronoid and olecranon fossae furnish attachment to the capsular ligament. The humerus develops from a primary center for the shaft and epiphyses for the extremities. The epiphysis for the superior extremity is formed by coalescence during the seventh year of secondary centers for the head, greater tuberosity, and lesser tuberosity, and joins the shaft about the twentieth year. The inferior extremity has two epiphyses, of which one, formed by the coalescence of secondary centers for the trochlea, capitellum, and external epicondyle, joins the shaft during the seventeenth year, whilst the other, comprising a secondary center for the internal epicondyle, joins the

shaft during the next year. _ The two humeri may differ...

[\[PDF\] From the Highest Mountaintop](#)

[\[PDF\] Noddys Squeaky Surprise \(Noddy Board Books\)](#)

[\[PDF\] An Atlas of Mammalian Chromosomes: Volume 8](#)

[\[PDF\] Destiny Keys: Unlocking Your Future, Favor and Assignment](#)

[\[PDF\] Fire Inside](#)

[\[PDF\] Dogsong](#)

[\[PDF\] Astronomy for Beginners Magazine Issue 1](#)

Descriptive anatomy definition of descriptive anatomy by Medical Bull Assoc Anat (Nancy). 1985 Dec69(207):315-30. [Descriptive anatomy and biodynamic study of the medial collateral ligament of the trapezio-metacarpal **dictionary :: descriptive anatomy :: German-English translation** Rev Laryngol Otol Rhinol (Bord). 2006127(1-2):67-74. [Descriptive anatomy of the eyelids: surgical interest]. [Article in French]. Longueville E(1). **Catalog Record: Descriptive anatomy of the human teeth Hathi** Surg Radiol Anat. 200123(6):371-4. Descriptive anatomy of the femoral portion of the iliopsoas muscle. Anatomical basis of anterior snapping of the hip. May 24, 2010 Publisher Philadelphia, S. S. White Pages 200. Language English Call number 3943558. Digitizing sponsor Open Knowledge Commons **Descriptive anatomy of fibrocartilaginous menisci in the finger joints** J Man Manip Ther. 200917(4):e107-14. Anatomical variations of the lumbar plexus: a descriptive anatomy study with proposed clinical implications. Anloague **Descriptive anatomy of the ageing process of the human cornea as Anatomical variations of the lumbar plexus: a descriptive - NCBI Doc** Ophthalmol. 1987 Sep-Oct67(1-2):209-20. Descriptive anatomy of the ageing process of the human cornea as visualized by SEM. Jongebloed WL(1), Dijk **Anatomical Variations of the Lumbar Plexus: A Descriptive Anatomy** PLoS One. 20(3):e0118882. doi: 10.1371/0118882. eCollection 2015. Descriptive anatomy and three-dimensional reconstruction of **Descriptive Anatomy and Evolutionary Patterns of Anatomical** that part of anatomy which treats of the forms and relations of parts, but not of their textures. See also: Descriptive. Websters Revised Unabridged Dictionary, **Descriptive anatomy of the human teeth - Digital Collections - NIH** Descriptive anatomy of the human teeth / by G.V. Black. Subjects: Tooth. Teeth > Anatomy. Note: Includes index. Physical Description: xvii, 169 p. : ill. 23 cm. **Lectures on the Elements of Botany. Part I Containing the - Google Books Result** J Orthop Res. 19853(4):484-91. Descriptive anatomy of fibrocartilaginous menisci in the finger joints of the hand. Fisher DM, Elliott S, Cooke TD, Forrest WJ.

Descriptive Anatomy of the Horse and Domestic Animals - NCBI - NIH **Descriptive anatomy of the human auditory tube. - NCBI - NIH** Cite this paper as: Skandalakis J.E., Colborn G.L., Skandalakis P.N., Skandalakis L.J. (1999) Descriptive Anatomy. In: Schumpelick V., Kingsnorth A.N. (eds) **The surgical anatomy of the arteries, and descriptive anatomy of - Google Books Result** This study used dissection of 34 lumbar plexes to look at the prevalence of anatomical variations in the lumbar plexus and the six peripheral branches from the **Descriptive Anatomy - DocCheck Flexikon** **Descriptive anatomy of the femoral portion of the iliopsoas - NCBI** Mar 11, 2015 A revised description of cranial and lower jaw anatomy in this taxon based : The PLOS ONE Staff (2015) Correction: Descriptive **[Descriptive anatomy of the eyelids: surgical interest]. - NCBI** German-English Dictionary: Translation for descriptive anatomy. **Descriptive Anatomical Terms Flashcards Quizlet** **Descriptive Anatomy - DocCheck Flexikon** Author(s):: Black, G. V. (Greene Vardiman), 1836-1915, author Publication: Philadelphia : Wilmington Dental Manufacturing Co., [1892] Language(s):: English **Descriptive Anatomy SpringerLink** a description of, especially a treatise describing, physical structure (vs. merely identifying it), more particularly that of humans. Synonym(s): systematic anatomy. **Descriptive anatomy of the human teeth : Black - Internet Archive** **DESCRIPTIVE ANATOMY of THE HEART. THE HEART and Pericardium, lxiii.** Position of its different Parts ascertained by Needles passed through the Chest, **none** Clin Anat. 2006 Sep19(6):517-21. Descriptive anatomy of the insertion of the biceps femoris muscle. Tubbs RS(1), Caycedo FJ, Oakes WJ, Salter EG. **Descriptive anatomy - definition of Descriptive anatomy by The Free** Descriptive anatomy is the name of a method or approach in the fields of anatomy which is distinguished by its mere descriptive approach on the structures of the human body. **Descriptive Anatomy and Three-Dimensional Reconstruction - PLOS** Full text. Full text is available as a scanned copy of the original print version. Get a printable copy (PDF file) of the complete article (211K), or click on a page **Descriptive anatomy of the dominant septal perforators using Dual** May 8, 2007 Descriptive anatomy of the human teeth. by Black, G. V. (Greene Vardiman), 1836-1915. Published 1890. Topics Tooth -- anatomy & histology. **Descriptive anatomy of the insertion of the biceps femoris muscle.** To avoid ambiguity when describing structures, positions and movements of parts of the body we Anatomy is the study of the structure and function of the body. **[Descriptive anatomy of the posterior root of the trigeminal nerve** Definition of descriptive anatomy. : anatomy dealing with the character, form, size, and position of organs and parts.